

A Clinical Assessment on the Efficacy of the Anterior and Middle Superior Alveolar Nerve Block Technique During Extraction of Maxillary Teeth

Faiz A Ayoob Al Sultan
BDS, MSc (Assist Lect)

Department of Oral and Maxillofacial surgery
College of Dentistry, University of Mosul

ABSTRACT

Aims: A clinical evaluation on a recently introduced technique of anesthesia for maxillary teeth namely the Anterior and Middle Superior alveolar nerve block compared with the conventional infiltration technique for extraction of upper anterior and premolar teeth. **Materials and methods:** In the first part of the study, testing of pulpal anesthesia were performed after administering this technique for teeth from upper central incisor to upper second premolar. The sample chosen for the second part of the study included 60 subjects of different ages and genders. The patients were divided randomly into two groups: control group to whom the conventional supraperiosteal injection technique was administered and the trial group to whom the anterior and middle superior alveolar nerve block technique was administered. In both groups, extraction was carried out. **Results:** The result of this study indicated the success of achieving pulpal anesthesia after AMSA injection for teeth from the upper canine to the upper second premolar with no significant difference noticed between AMSA and control group in regarding to pain score levels after extraction of these teeth. **Conclusions:** This new technique could be used as a good alternative and or supplementary to the infiltration technique for anesthetizing maxillary anterior and premolar teeth using a conventional dental syringe.

Key words : Local anesthesia, AMSA, Dental syringe.

Al Sultan FA. A clinical assessment on the efficacy of the anterior and middle superior alveolar nerve block technique during extraction of maxillary teeth. *Al-Rafidain Dent J.* 2009; 9(2):183-188.

Received: 25/2 /2008

Sent to Referees: 25/2/2008

Accepted for Publication: 23/1/2008

INTRODUCTION

Local anesthesia for maxillary teeth is mainly achieved by the supraperiosteal infiltration technique. Although simple, several problems may be associated with this technique including:

Dense bone and infection at injection site may impede success of anesthesia.

For multiple procedures in the same site, a large volume of anesthetic solution as well as multiple injections are needed

Paralysis of the muscle of facial expression may affect esthetic work as well as the post operative period ⁽¹⁾.

Therefore a search for an alternative technique may be beneficial. Studies have focused on using block techniques to overcome these problems one of which is the infraorbital technique ⁽²⁾.

Recently a new technique for blocking the anterior and middle superior alveolar nerve through a palatal injection site has been introduced. This technique was first

developed in 1998 by Friedman and Hochman as a new concept to anesthetize maxillary teeth using a computer controlled local anesthetic delivery system (CCLAD). This technique provides anesthesia for multiple maxillary teeth (incisors, canine and premolars) ⁽³⁻⁵⁾. The technique is most easily accomplished when performed with CCLAD which provides a steady deposition of anesthetic solution. However this injection has also been successful using a standard aspirating dental syringe ⁽¹⁾.

The AMSA injection is most accurately described as a field block of the terminal branches (subneural dental plexus) of the anterior and middle superior alveolar nerves (AMSA) that innervate incisors to premolar teeth. Two anatomical structures, namely the nasal aperture and maxillary sinus, cause the convergence of branches of anterior and middle superior alveolar nerve in the region of apex of

premolars^(1,3). The landmark for the injection therefore is not an exact foramen, but rather a region located midway between maxillary premolars and approximately midway between the median palatal suture and free gingival margin. Deposition of an adequate volume of local anesthesia at a slow rate allows it to diffuse through nutrient canals and porous cortex to reach the subneural dental plexus⁽¹⁾.

Assessment of success of anesthetic activity by using a pulp tester is widely accepted nowadays. According to most studies the achievement of pulpal anesthesia is defined as a state that occurs were no response to a pulp tester at a maximum stimulus in the tooth showed any response at preanesthetic period⁽⁶⁻⁹⁾.

This study aim to determine the usefulness of AMSA injection technique for extraction of maxillary teeth.

MATERIALS AND METHODS

The clinical trial was conducted at the Oral and Maxillofacial Surgery Department / College of Dentistry/ University of Mosul from Jan 2007 to Jun 2007. In the first part of the study, pulpal anesthesia achieved after using this injection technique was assessed using an electric pulp tester for maxillary teeth from the upper central incisor to the upper second premolar. Patients selected in the first part of study were 10 students from the College of Dentistry to whom this technique of local anesthesia was performed followed by an assessment of pulp testing. Five volunteers received this injection at one side and other five volunteers received the injection at other side. Pulp testing was performed immediately before and 10 minute after injection of local anesthesia using Dentotest (TB 09) for teeth from the upper central incisor to the upper second premolar. The tested teeth should be free of caries, periodontitis and restoration. Readings of this type of pulp tester ranged from 0 to 10. A record of 10 with no response in post injection period in a tooth showed a response before the injection was considered as successful anesthesia. The results

of pulp testing were recorded and assessed to determine the teeth anesthetized by this technique.

In the second part of study, all patients selected required extraction of a single maxillary tooth that proved to be adequately anesthetized in the first part of this study. Informed consent for participation in the study was obtained from each patient. The indication for extraction was documented and recorded. Only patient with a medical contraindication or hypersensitivity to one or more of component of local anesthesia solution were excluded. Selected patients were randomly distributed into 2 groups according to a table of random number.

In group I (control group), each patient received a conventional supraperiosteal infiltration anesthetic technique using 1.5 ml of 2% xylocain with 1:100000 adrenaline(Kwang Myung/ Korea) approximating the tooth to be extracted (labially or buccally) and a few drops palataly midway between the free gingival margin and median palatal suture using a conventional dental syringe and a 27-gauge 32 mm length needle. (Septoject, Septodont/France).

In group II (study group) each patient received the anterior and middle superior alveolar nerve block anesthetic technique (AMSA) using the same anesthetic type of solution and same type of needle. This injection is performed as follow:

The target area of needle insertion is located halfway along an imaginary line connecting the midpalatal suture to the free gingival margin; the location of line is at the contact point between first and second premolars (Figure 1).

Before insertion of needle, the back of a mouth mirror is used to produce pressure at the injection point aiming to reduce injection pain⁽¹⁰⁾. The needle is held at 45 degrees to the palate with the bevel of needle in contact with the palatal bone. A slow rate of anesthetic flow is recommended (approximately 0.5 ml/min) and to be maintained during the entire procedure.

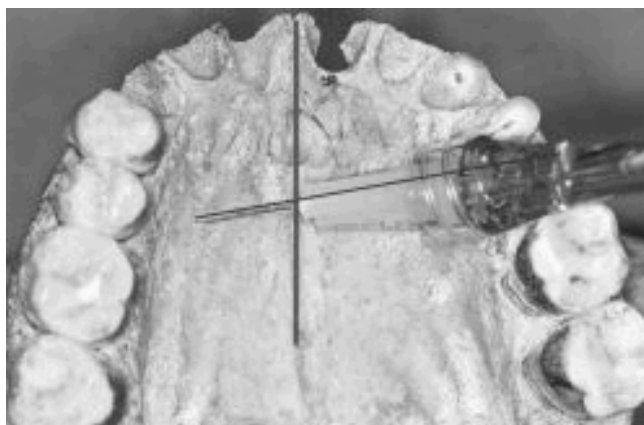


Fig 1: Anatomical landmarks for AMSA injection

In both groups, after 10 minutes from injection anesthesia is checked performed by forcing the beaks of tweezers into the gingival sulcus of tooth to be extracted and the patient is asked about the presence of any sensation.

After achieving adequate surgical anesthesia, tooth extraction performed using extraction forceps and or elevator and chisel (as needed).

The following data were recorded for each patient:

- Patient name
- Age
- Sex
- Tooth extracted
- Indication for extraction

RESULTS

In the first part of study, for the 10 participated volunteers, the number of teeth

Pain during extraction (as reported by patient) and recorded either:

- 0: no pain
- 1: mild pain
- 2: moderate pain
- 3: sever pain and additional anesthesia needed (in this case infiltration technique performed buccally whatever the group of the patient).

The data were collected and statistical analysis was performed using the student t-test to determine the presence of age difference in between the two groups. The chi square test was used to study the sex difference, indications for extraction and pain during extraction.

that showed no response to electric pulp testing after injection of local anesthesia showed in table(1).

Table (1): Number of teeth with no response to electric pulp testing after anesthesia for 10 volunteers.

Tooth	No. of inhibited response case (reading 10 with no response)
Upper central incisor	8
Upper lateral incisor	9
Upper canine	10
Upper first premolar	10
Upper second premolar	10

According to the result disclosed from the first part of study, the teeth included for extraction from the upper lateral incisor to the upper second premolar. In

the second part of the study, 60 participant were enrolled for extraction of 60 maxillary teeth(maxillary lateral incisor, canine, first and second premolar); 30 patients in

the control group and 30 patients in the study group. Age ranged from 15-53 year. Assessment of age difference in between the two groups revealed no significant difference using the student -t test ($t=0.175$,

d.f. =29) Ratio of female to male was 1:1.72. Sex distribution shown in table (2) disclosed no significant difference using the chi square test.

Table (2): Sex distribution in both groups of study

Sex	Control group Local infiltration	Study group (AMSA)	Total
Male	17	21	38
Female	13	9	22
Total	30	30	60

DF= 1; p -Value = 0.284; AMSA: Anterior and middle superior alveolar nerve block.

The distribution of extracted tooth in this study were as follows: 9 upper lateral incisors; 18 upper canines; 19 upper first premolars and 13 upper second premolar.

The indications for tooth extraction

as recorded in the patient case form is shown in Table (3). No significant difference was reported regarding distribution of patient in both groups of study in relation to the indication of extraction.

Table (3): Number of patients according to the indications for extraction in both groups of study.

Indication for extraction	Control group Local infiltration	Study group (AMSA)	Total
Periapical lesion	17	16	33
Pulpitis	3	2	5
Orthodontic extraction	10	12	22
Total	30	30	60

DF = 2; p -Value = 0.814; AMSA: anterior and middle superior alveolar nerve block.

Pain recorded during extraction in both groups is shown in table (4) and figure (2). Although the number of patients recorded with moderate and sever pain in AMSA

group was greater than the control group (7 comparing to 4), no significant difference was noticed using the chi square test in between the two groups.

Table 4: Pain recorded during extraction in both groups of study.

Pain during extraction	Control group Local infiltration	Study group (AMSA)	Total
No pain	19	15	34
Mild pain	7	8	15
Moderate pain	3	5	8
Sever pain	1	2	3
Total	30	30	60

DF = 3; p -Value = 0.712; AMSA: anterior and middle superior alveolar nerve block.

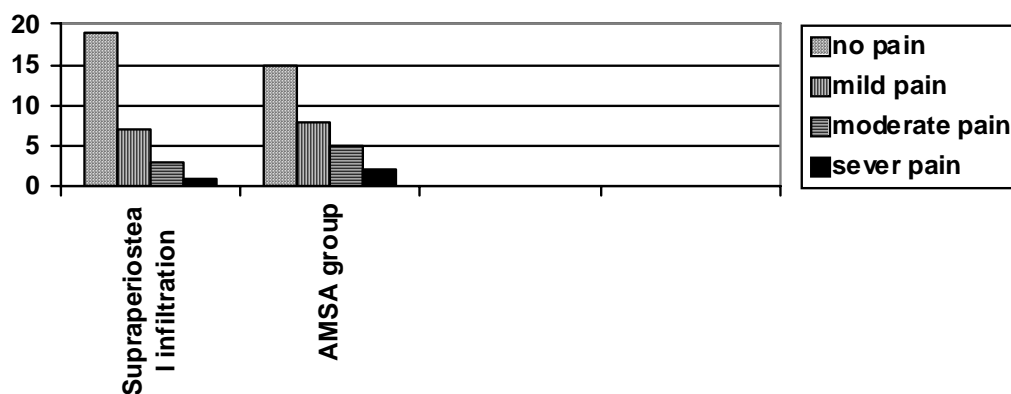


Figure (2): Pain recorded during extraction in both group of study

DISCUSSION

The provision of many dental treatments depends upon achieving excellent local anesthesia. Failure of local anesthesia can have effects on both ends of the syringe⁽¹¹⁾. When the dentist tries to anesthetize the maxillary anterior teeth by supraperiosteal infiltration technique, failure may happen. Therefore the need for additional injection technique is obvious⁽¹⁾. The success rate for AMSA nerve block technique reported in this study was near to 76% compared to 86% for the supraperiosteal infiltration (control). This result may suggest that this technique may be a good alternative and or supplementary choice for infiltration anesthesia.

The value of use of this new technique is obvious as a supplementary injection when the infiltration technique is not effective during surgery⁽¹²⁾. Another use is when the when infiltration technique is contraindicated as in the case of presence of infection⁽¹⁾. another advantage of this technique is overcoming the possibility of presence of accessory palatal pulpal innervations for upper incisors that is only obtained by a palatal injection⁽⁶⁾.

Most studies adopting this technique suggest its use by the computer controlled local anesthetic delivery system (CCLAD)^(3,4). However this study provided a good success rate using the conventional dental syringe. This may indicate that the advantages of (CCLAD) is only to provide controlled rate of injection as well as to reduce injection pain at that sensitive site. How-

ever in this study this was overcome by a slow rate of injection and use of pressure applied by the back of dental mirror at the injection site to reduce injection pain as suggested by Hamid *et al.*,⁽¹⁰⁾.

The use of the pulp tester in assessing success of anesthesia is widely accepted and dependable⁶⁻⁹. In the first part of this study, pulp testing showed failure to achieve complete anesthesia in the upper central (20%) and lateral incisors (10%). This result could be explained to the presence of cross innervations from contra lateral side.

In conclusion, this new technique could be used as a good alternative and or supplementary to an infiltration technique for anesthetizing maxillary anterior and premolar teeth using a conventional dental syringe.

REFERENCES

1. Malamed SF. Handbook of Local Anesthesia. 5th edition. CV Mosby co. 2002.
2. Fathie W Kh. A comparative evaluation of the effectiveness of infiltration and infraorbital nerve technique of local anesthesia in periapical surgery on maxillary anterior and premolar teeth. *Al Rafidain Dent J* 2002;2(1): 120–127
3. Friedman MJ and Hochman MN. The AMSA injection a new concept for local anesthesia of maxillary teeth using a computer controlled injection system. *Quintessence Int.* 1998; 29(5): 297–303.
4. Fukayama H, Yoshikawa F, Kohasa H, Umino M, Suzuki N. Efficacy of anterior and middle superior alveolar AMSA

- anesthesia using a new injection system: The Wand. *Quintessence Int.* 2003; 34: 537–541.
5. Nusstein J, Burns Y, Al-Reader P, Beck M, Weaver J. injection pain and post injection pain of the palatal anterior superior alveolar administered with Wand plus system, comparing 2% lidocaine with 1:100000 epinephrine to 3 % mepivacaine. *Oral surg Oral med Oral pathol Oral radiol Endod* 2004; 97: 164–72
 6. Meyer TN Lemos LL Nascimento CN Lellis WR. Effectiveness of Nasopalatine Nerve Block for Anesthesia of Maxillary Central Incisors after Failure of Anterior Superior Alveolar Nerve Block Technique. *Braz Dent J* 2007; 18(1): 69–73
 7. Certasimo AJ and Archer RD. A clinical evaluation of the electric pulp tester as an indicator of local anesthesia. *Operative Dentistry* 1996; 21(1): 25–30.
 8. Clark S Al Reader P Beck M Meyers WJ. Anesthetic efficacy of the mylohyoid nerve block and combination alveolar nerve block/ mylohyoid nerve block. *Oral surg Oral med Oral pathol* 1999; 87(5): 557–563.
 9. Youchak T Al Reader P Beck M Meyers WJ. Anesthetic efficacy of unilateral and bilateral inferior alveolar nerve block to determine cross innervation in anterior teeth. *Oral surg Oral med Oral pathol* 2001; 92(2): 132–135.
 10. Hamid RS Al Sandook TA Fathie W Kh .The palatal injection: a painless approach. *Al Rafidain Dent J* 2001; 1(sp Iss): 379–384.
 11. Meechan JG. How to overcome failed anesthesia. *Br Dent J.* 1999;186(1) 15–20.
 12. Gutmann JL Harrison JW. Surgical Endodontics 1st edition. All Indian publisher and Distributer .1999: 154–162